

Digital quantitation of fibrosis, septa parameters and treatment-induced changes in metabolic dysfunction-associated steatohepatitis F3 fibrosis

Nikolai V. Naoumov¹, David E. Kleiner², Elaine Chng³, Dominique Brees⁴, Chandra Saravanan⁵, Yayun Ren³, Dean Tai³, Arun J. Sanyal⁶

¹London, United Kingdom, ²Post-Mortem Section, Laboratory of Pathology, National Cancer Institute, 10 Center Drive, Building 10, Bethesda, MD 20892, United States, ³Histoindex Pte. Ltd., Singapore, ⁴Novartis Pharma AG, Basel, Switzerland, ⁵Novartis Institute of Biomedical Research, Cambridge, MA, United States, ⁶Stravitz-Sanyal Institute of Liver Disease and Metabolic Health, Virginia Commonwealth University School of Medicine, Richmond, United States



Paris
NASH
Meeting



BACKGROUND AND AIMS

- Metabolic dysfunction-associated steatohepatitis (MASH) with bridging fibrosis (stage F3) is a critical stage in the evolution of steatotic liver disease, which can progress to cirrhosis or reverse to milder disease with better prognosis.
- Second Harmonic Generation/Two Photon Excitation Fluorescence (SHG/TPEF) microscopy of unstained liver sections with Artificial Intelligence (AI) provides sensitive and reproducible quantitation of liver fibrosis.
- The aim was to apply SHG/TPEF and AI analysis based digital pathology for quantitative evaluation of liver fibrosis and individual septa parameters in MASH patients with bridging fibrosis (F3 stage) and compare these with conventional histology assessment.

METHODS

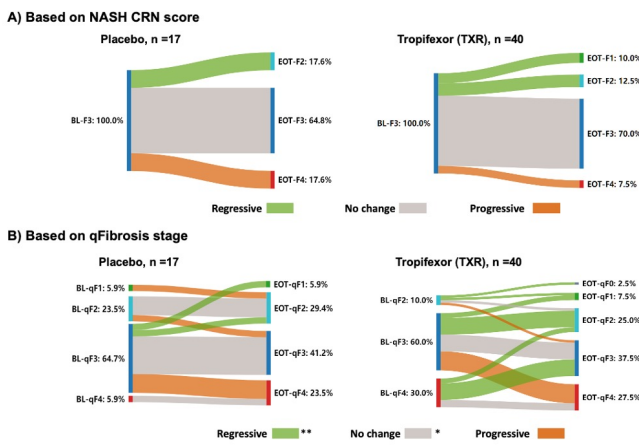
- Paired liver biopsies from 57 patients [placebo, n=17 or Tropifexor (TXR) n=40], all with bridging fibrosis (F3 stage) according to the NASH-CRN scores at Baseline (BL) from the FLIGHT-FXR clinical trial (NCT02855164) were included.
- Unstained liver sections from BL and End-of-Treatment (EOT) were examined using SHG/TPEF microscopy and liver fibrosis overall, in five different zones of liver lobules, plus 12 septa parameters were quantitatively assessed.

RESULTS

Figure 1A: Most cases (65% in placebo, 70% in TXR) were classified as "F3 No-change" according to NASH-CRN score.

Figure 1B: In contrast, digital quantitation identified greater diversity of fibrosis stage at BL, and a large proportion of cases showed fibrosis progression or regression (Figure 1B) according to qFibrosis stage.

- Additionally, the amount of fibrosis was quantitated in 5 regions of liver lobule – Portal, Peri-portal, Zone 2 Perisinusoidal, Peri-central region, and Bridging fibrosis.
- The results (n=17 placebo, n=40 TXR) were represented by radar maps as an approach for illustrating fibrosis dynamics.
- Patients were divided into 3 subgroups: A) Those whose fibrosis decreased, B) Increased, or C) No-change from BL to EOT according to NASH-CRN scoring.
- The radar map for placebo group revealed significant fibrosis increase in perisinusoidal fibrosis, while in some patients treated with TXR, significant fibrosis reduction was detected in the portal, peri-portal areas and bridging fibrosis.



* p < 0.05; ** p < 0.01 for the comparison between placebo and TXR groups.

Figure 1: Liver fibrosis changes (BL to EOT) as assessed by conventional scoring (NASH-CRN) and by qFibrosis using SHG.

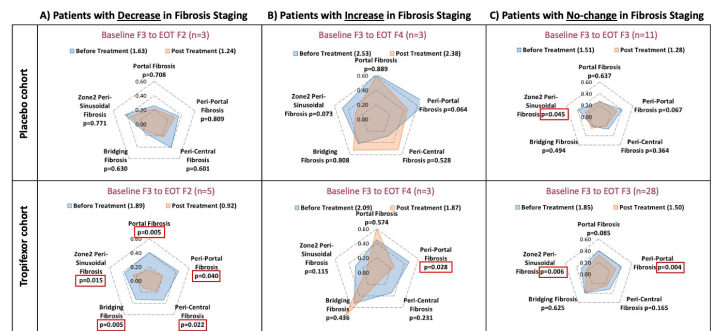


Figure 2: qFibrosis changes (BL to EOT) presented as a radar map in patients who received placebo or Tropifexor.

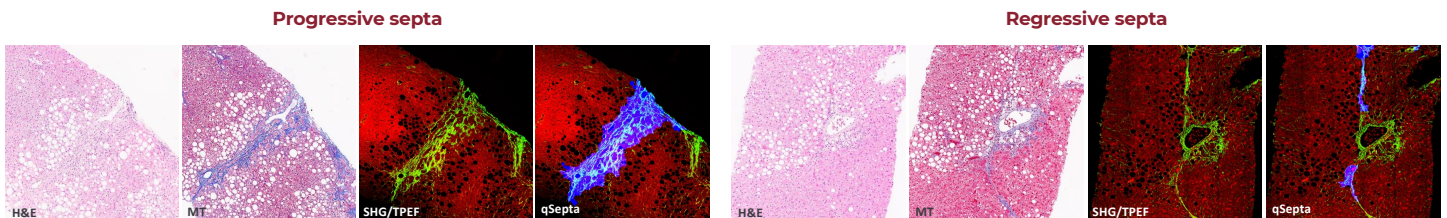


Figure 3: Example of progressive and regressive septa with conventional staining method and digital SHG microscopy of the unstained liver tissue.

CONCLUSIONS

- SHG/TPEF microscopy with AI analysis provides greater granularity and precision in assessing fibrosis dynamics in MASH patients with bridging fibrosis and reveals worsening or improvement undetectable by conventional microscopy, enhancing the understanding of disease pathogenesis and treatment response.
- These results support the use of digital pathology approaches for quantitative fibrosis assessment, in the natural history and treatment of MASH and other liver diseases.