

# Quantification of Septa in Liver Fibrosis using Second Harmonic Generation Imaging

Li Chen<sup>1</sup>, Mohammad Naser<sup>2</sup>, Mathieu Petitjean<sup>1</sup>

<sup>1</sup> Genesis Imaging Services, PharmaNest, Princeton, NJ, USA

<sup>2</sup> Rutgers University, New Brunswick, NJ, USA

## ABSTRACT

### Background

Liver fibrosis is associated with excessive accumulation of extracellular matrix in response to persistent injury, inflammation, and abnormal wound healing. A common method to assess liver fibrosis is by conventional staining and histopathological evaluation using i.e. Metavir Scoring. This assessment has limitation as it uses a narrow range scoring, a qualitative septa counts, and it is also prone to observer variations. Collagen quantitation in the conventional method refers to only total collagen and lacks description on the fibrous septa. Here we use second harmonic generation (SHG) together with two-photon excitation fluorescence (2PE) imaging and machine-learning image analysis algorithm to provide a more in depth look at the changes in the fibrous septa as fibrosis development advances or regresses from a stained-free histological tissue section.

### Method

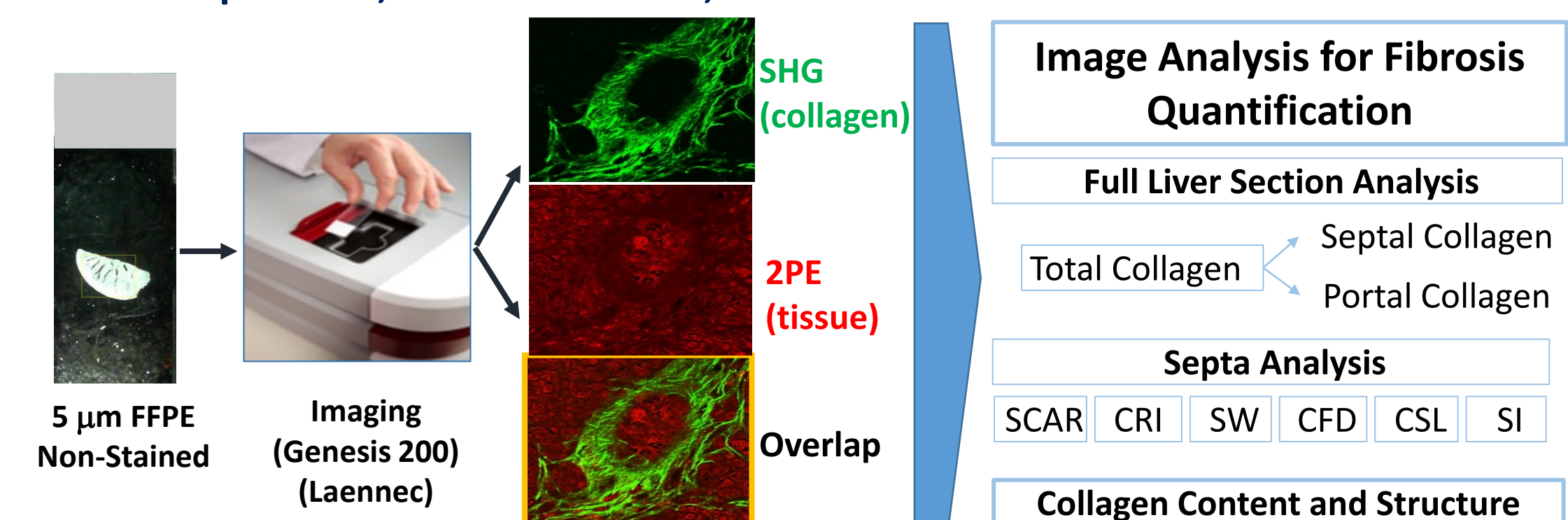
In this study, mice are treated with olive oil (control) or carbon tetrachloride (CCI4) with or without an anti-fibrotic drug, Pirfenidone. CCI4 is a hepatotoxicant used to induce liver fibrosis. FFPE liver histological sections (5µm) were imaged (without staining) using Genesis 200<sup>®</sup>, a multi-photon optical digital imaging system, which combines SHG to produce collagen specific images (collagens I and III) and 2PE to delineate tissue morphology. We developed a robust, semi-automatic image analysis algorithm to extract information on the fibrous septa. Full liver section analysis metrics include Total, Vasculature (portal and central vein), and Septal Collagen. Metrics for fibrous septa include Septal Collagen Area, Reticulation index, Fiber Density, Thickness (width), Branches, and Segment Length.

### Results and Conclusion

The study result revealed that CCI4 induces liver fibrosis by not only increasing total collagen levels but also causes septa (quantifiable) characteristic changes. This induction was ameliorated with Pirfenidone. As fibrosis progress, there are significant changes as short thin fibrous septa developed into advanced bridging fibrosis. Majority of the septa show increase in collagen area accompanied by increase in collagen structure, which is a potential indicator of tissue stiffness. Fibrous septa are also thicker with more but shorter "tree" branches. SHG/ 2PE imaging is a novel stained-free imaging technique combined with a robust image analysis system to provide an semi-automated and fully quantitative extraction of information for liver fibrosis and the septa. This capability may help evaluate anti-fibrotic therapy efficacy during fibrosis progression and regression.

## METHOD

### Tissue Preparation, Instrumentation, and Workflow



- 5-200µM FFPE or Frozen sections
- Stain-Free and label-free imaging
- Fully quantitation of collagen and septa
- High Resolution (0.4 µM @ 20x)
- Non-destructive (tissue reusable)
- 2-Photon Excitation (2PE): auto fluorescence for tissue morphology depict cellular structure and injury
- Second Harmonic Generation (SHG): Collagens I and III
- Machine-learning Image Analysis Software optimized and validated with pathologists

### CCI4 Liver Fibrosis Model

Balb/c mice were treated (i.p. injection) with olive oil (Ctrl) or CCI4- olive oil mixed solution for 4wk and 6wk with or without Pirfenidone (PFD), an anti-fibrotic therapeutic drug.

Group 1	Group 2	Group 3	Group 4
Control	CCI4 (4wk)	CCI4 (6wk)	CCI4 (6wk) + Pirfenidone

### Liver Fibrosis Image Analysis

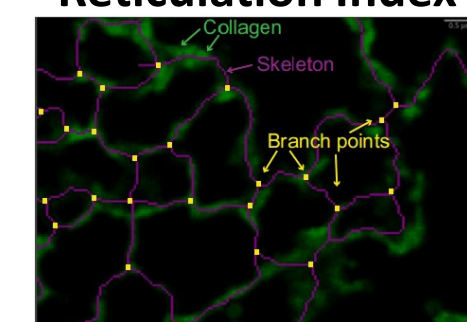
#### 1. Full Liver Section

- Regional segmentation (histology image and graph)
- Total (Vasculature + Septa), Vasculature (Portal), Septal Collagen
- 2D Fibrosis Chart

#### 2. Fibrous Septa Analysis

- Septal Collagen Area Ratio% (SCAR): area occupy by collagen in the region of interest
- Collagen Reticulation Index (CRI): measures collagen fiber network
- Septal Width (SW): width at 1/3<sup>rd</sup>, 2/3<sup>rd</sup> length of septa
- Septal Intersection(SI): # branches or intersections at 1/3<sup>rd</sup>, 2/3<sup>rd</sup> length of septa
- Collagen Segment Length (CSL): average length of the septal branches
- Collagen Fiber Density (CFD): collagen density within fiber, intensity directly proportional to amount collagen within fiber


#### Reticulation Index



#### Same Collagen Area



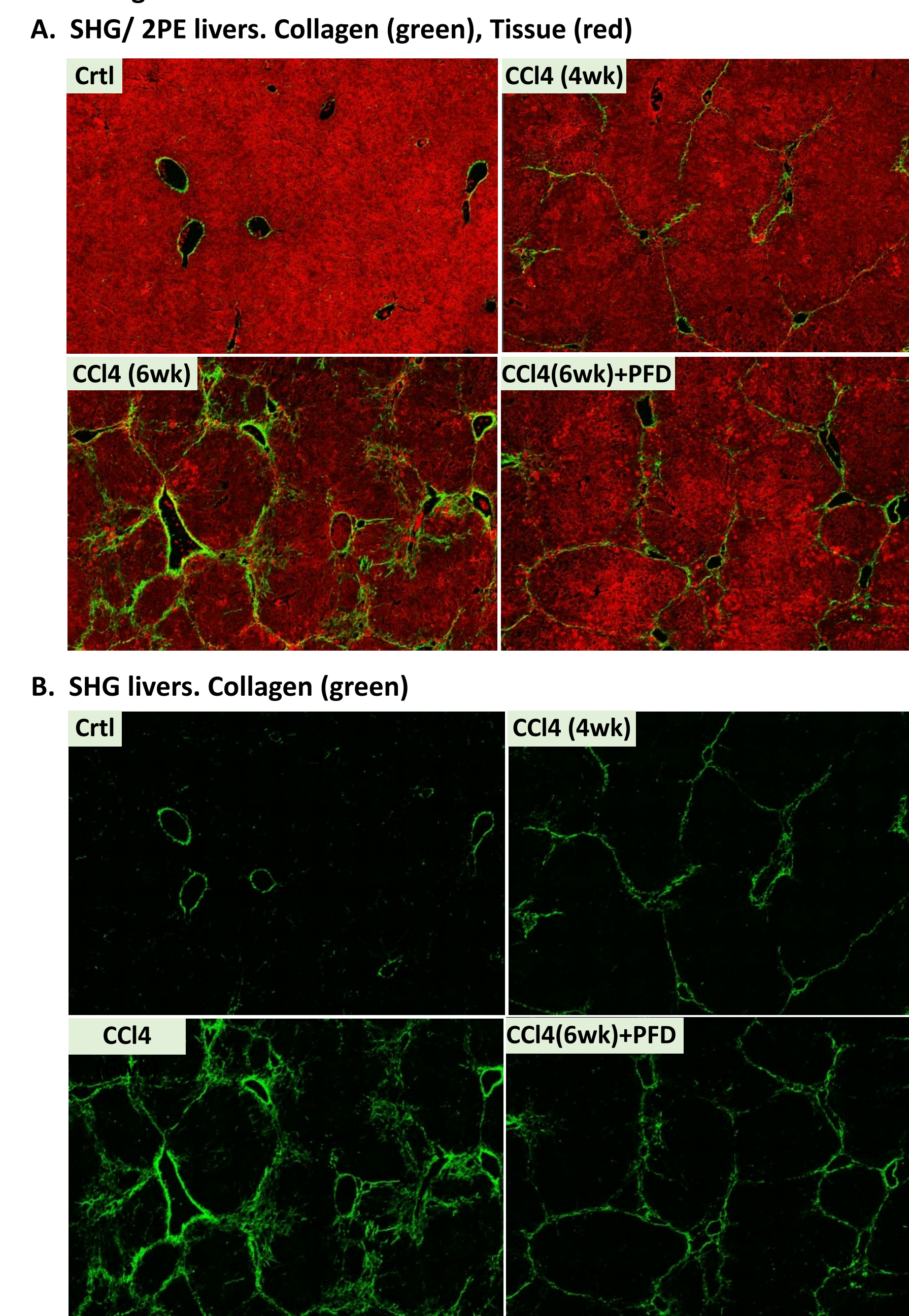
#### High Collagen Density



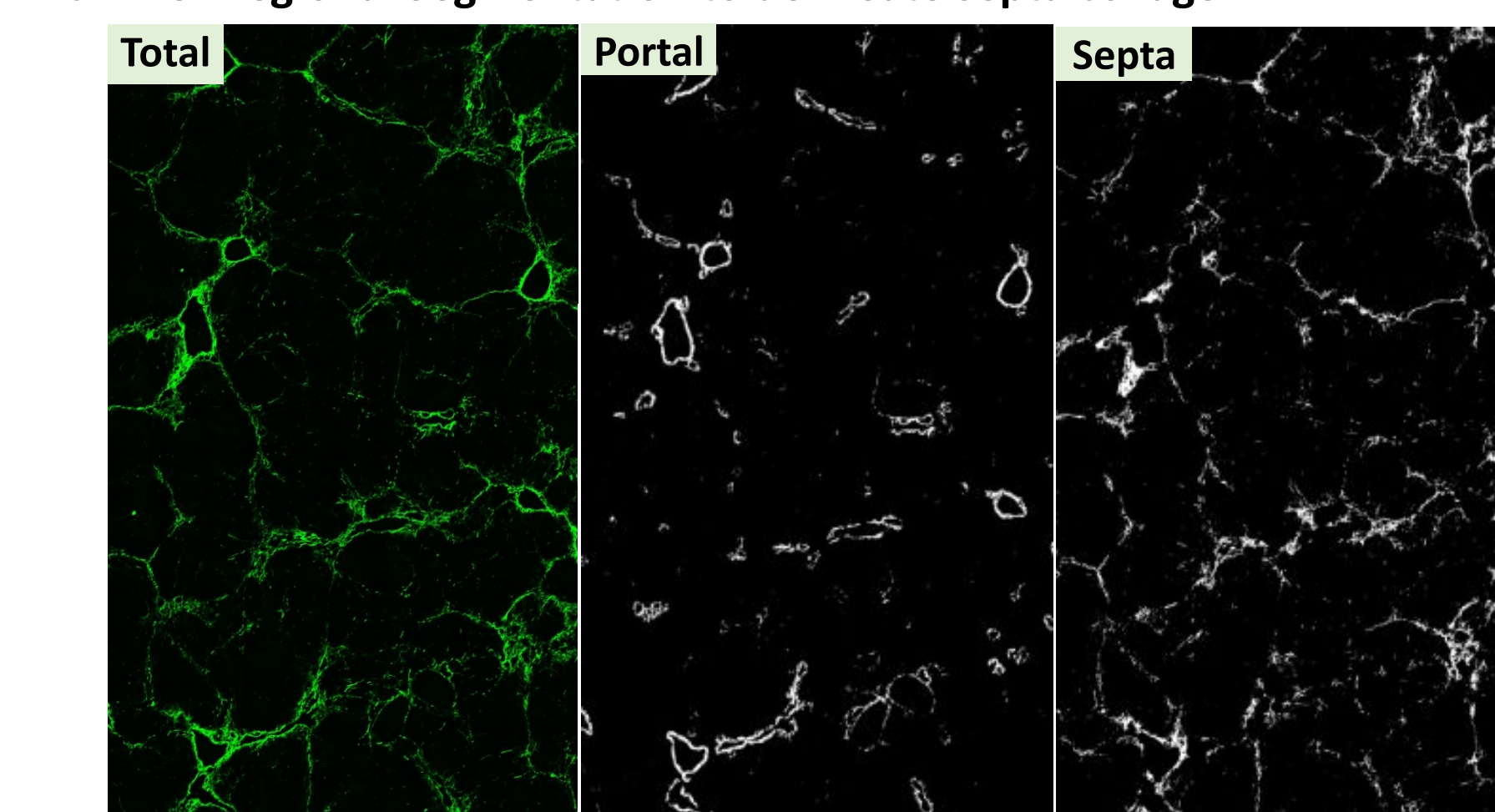
#### Low Collagen Density



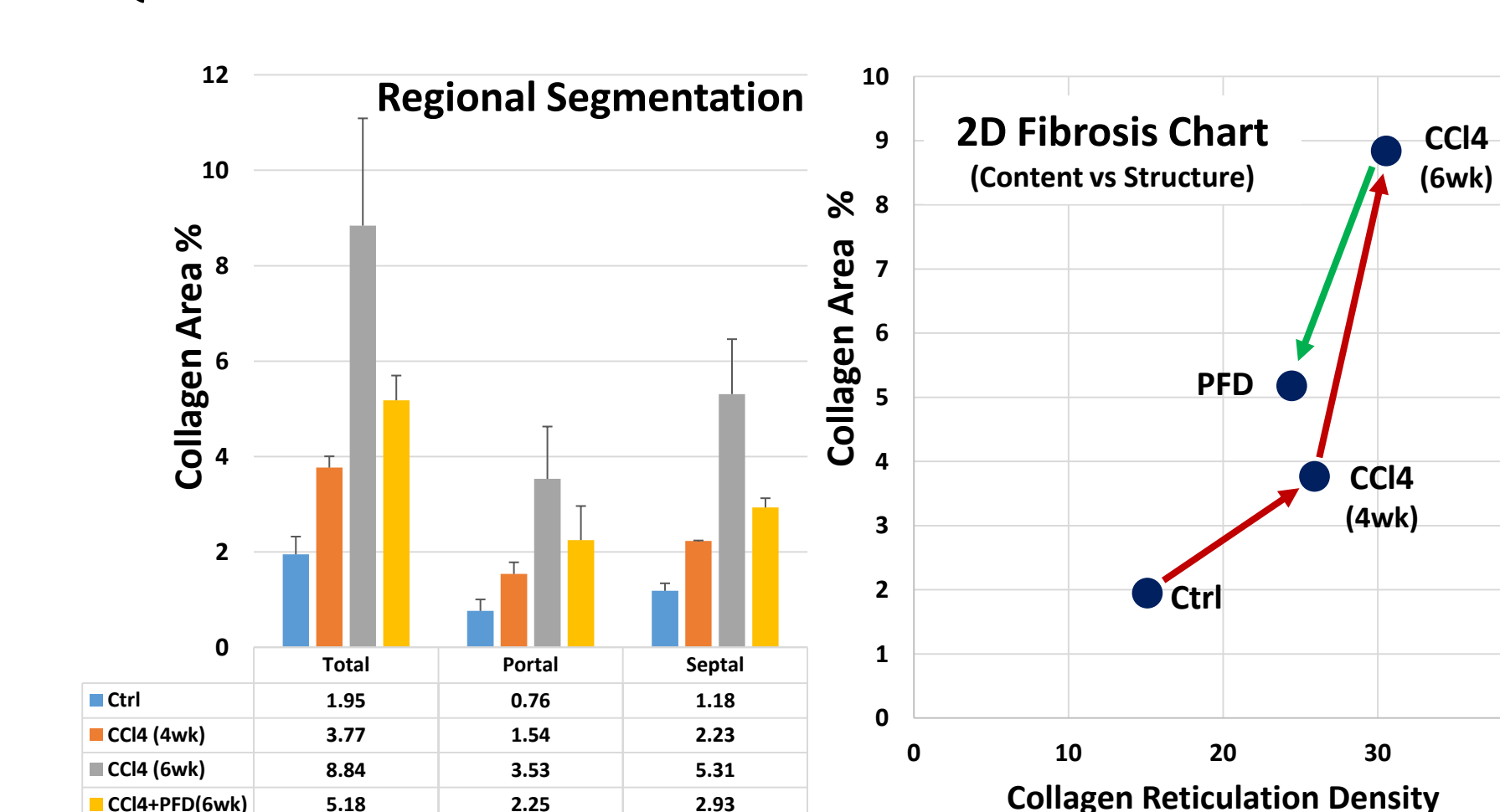
**Figure 1. CCI4-treated mice induces hepatic fibrosis and septa development in histological sections.**



**C. Liver Regional Segmentation to delineate septa collagen**

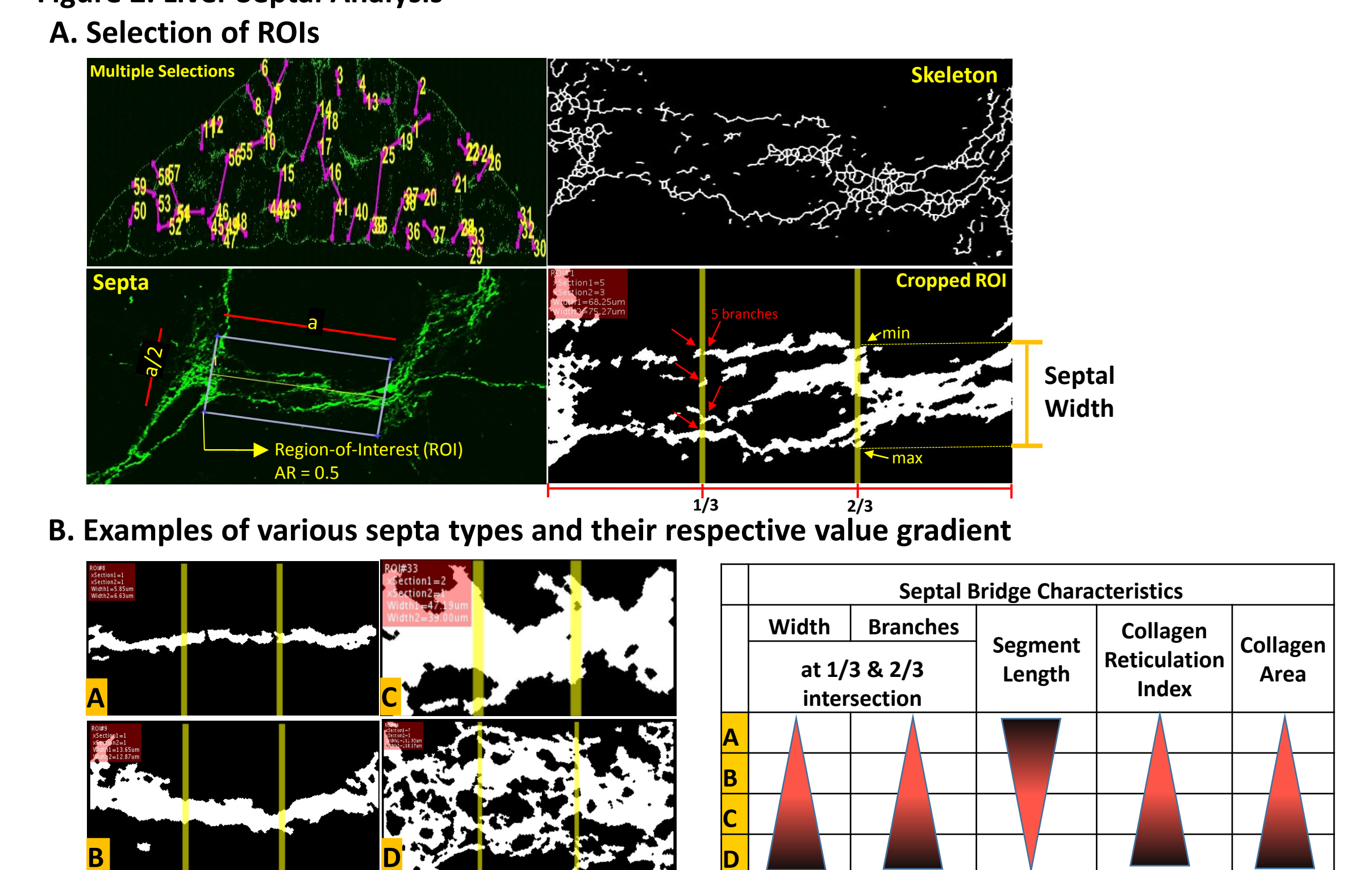


**D. Quantitation of Liver Fibrosis**

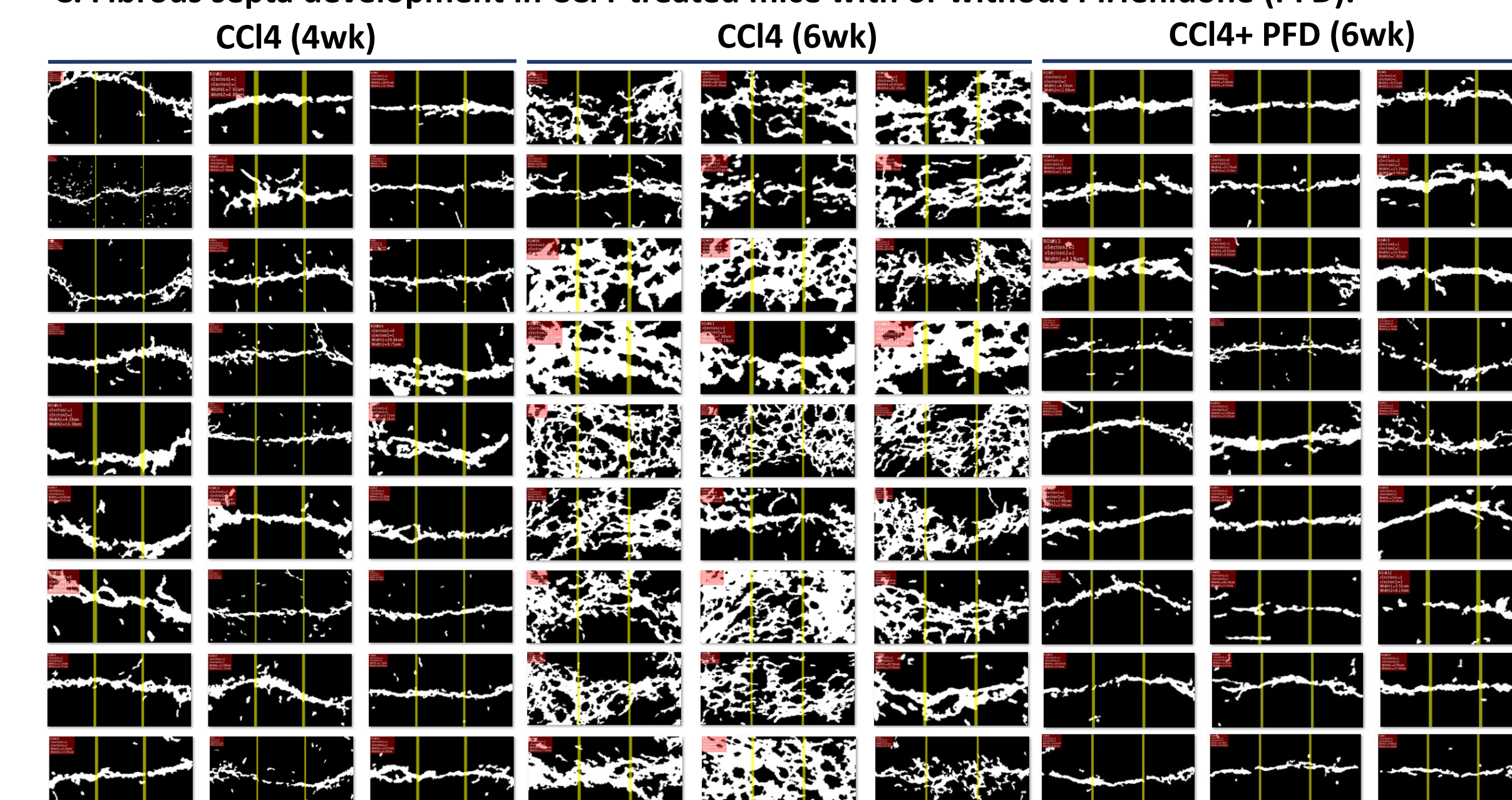


## RESULT

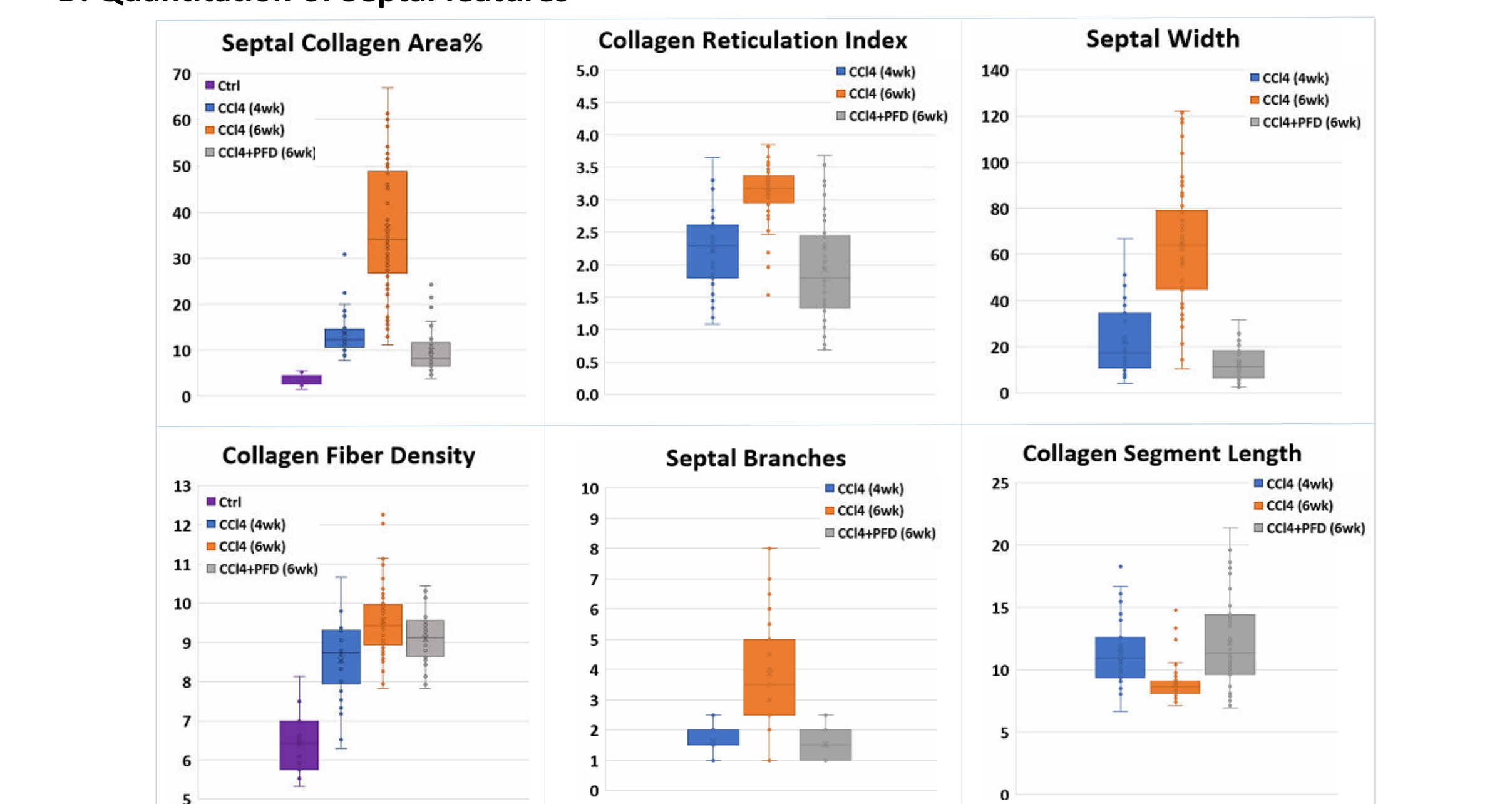
**Figure 2. Liver Septal Analysis**



**C. Fibrous septa development in CCI4-treated mice with or without Pirfenidone (PFD).**



**D. Quantitation of Septal features**



## Conclusion

- SHG/2PE imaging is a sensitive stain-free novel technique which when combined with semi-automated image analysis for liver fibrosis and septa helps to evaluate anti-fibrotic therapy efficacy during fibrosis progression and regression.
- In addition to basic metrics for total collagen content quantification, we offer novel analysis capabilities that conventional method are not able to provide such as collagen network structure, liver regional segmentation (segmenting vasculature and septa collagens from total tissue collagen), and fibrous septa analysis.
- Our Septa Analysis Tool delivers a more in-depth understanding of septa development and changes during liver remodeling using quantifiable metrics. These metrics maybe the key to better liver fibrosis scoring and staging.

**Acknowledgement:** We thank Naser for developing the Septal Analysis Tool at GIS. We also thank Kenneth Zhang at GenScript for collaboration on the CCI4 Liver Fibrosis Study shown in Figure 1.