

Efruxifermin significantly reduced proportion of participants with at-risk MASH and led to near-complete histological disease reversal at week 96 in the HARMONY study

M. NOUREDDIN¹, C. BEHLING², P. BEDOSSA³, L. SHAO⁴, E. CHNG⁵, Y. CHOUDHURY⁵, D. TAI⁵, D. CHAN⁶, E. FONG⁶, B. DE TEMPLE⁶, M. MINERVA⁶, M. BURCH⁶, K. BARRETT⁶, R. SHRINGARPURE⁶, E. J. TILLMAN⁶, T. ROLPH⁶, A. CHENG⁶, K. YALE⁶, S. A. HARRISON⁷

1. Houston Research Institute; Houston Methodist Hospital, Houston, TX, USA; 2. Department of Pathology, Sharp Memorial Hospital, San Diego, CA, USA; 3. Liverpat, Paris, France; 3. Institute of Cellular Medicine, University of Newcastle, Newcastle upon Tyne, UK; 4. Fortrea Inc, Raleigh, NC, USA; 5. HistoIndex Pte Ltd, Singapore, Singapore; 6. Akero Therapeutics, South San Francisco, CA, USA; 7. Pinnacle Clinical Research, San Antonio and Austin, TX, USA

INTRODUCTION

Efruxifermin (EFX) is a long acting, bivalent, modified human FGF21 fused to the Fc domain of human IgG1, currently being evaluated in Phase 3 clinical trials for treatment of MASH with fibrosis or cirrhosis.

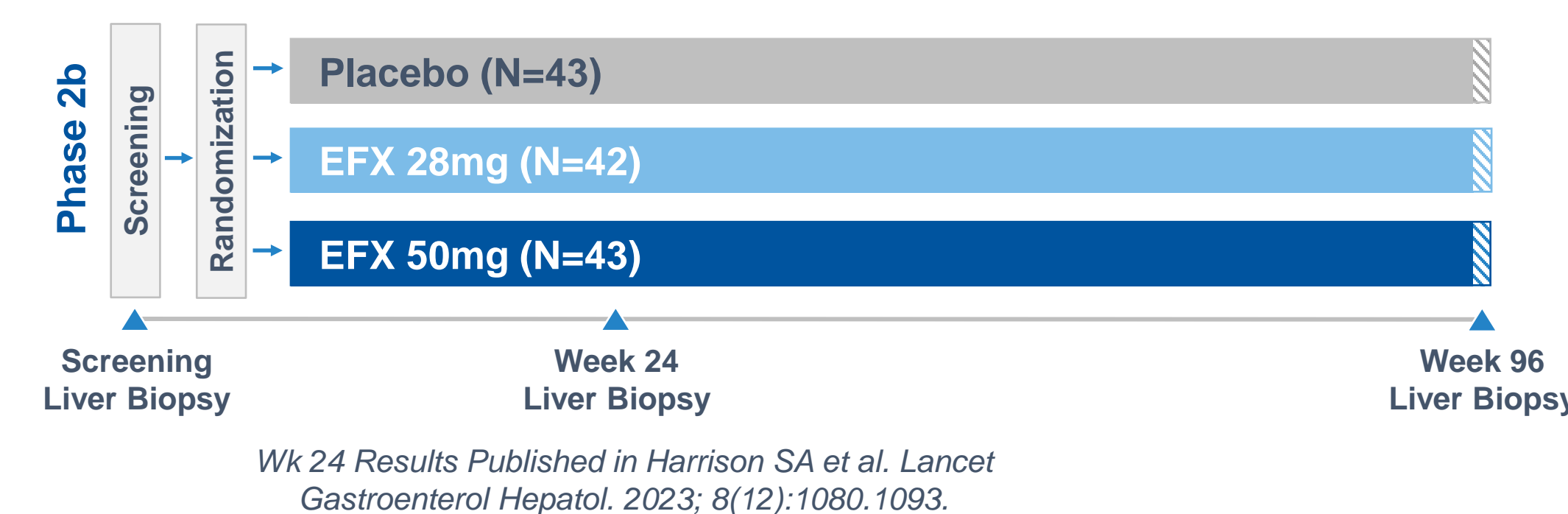
In a randomized, placebo-controlled Ph2b study in people with MASH and F2 or F3 fibrosis (HARMONY), EFX significantly improved liver histopathology at W24, with a sustained, expanded, and deepened antifibrotic response with continued treatment to W96. Over the course of 96 weeks, EFX had an acceptable safety and tolerability profile, with mostly mild-to-moderate GI events.

AIMS

To further characterize the histopathologic response to EFX and extent of disease reversal, ad hoc analyses combining stringent multimodal criteria were performed, and changes in liver histopathology were characterized by AI-based digital histopathology (qFibrosis®, HistoIndex).

METHODS

Figure 1. Trial Design: Pre-Cirrhotic (F2-F3) MASH with Liver Histology at 24 and 96 Weeks



STUDY PARTICIPANTS

Table 1. Baseline Demographics

Parameter (Units), mean unless noted	Placebo (N=43)	EFX 28mg (N=42)	EFX 50mg (N=43)
Full Analysis Set (all randomized participants)	N=43	N=42	N=43
Age (Years)	55	57	52
Sex (% Female)	63	69	53
Body Weight (kg)	108	104	103
Type 2 Diabetes (%)	65	76	70
Fibrosis Stage (F3), (%) ¹	70	64	63
Enhanced Liver Fibrosis (ELF) Score	9.8	9.7	9.8
Pro-C3 ² (µg/L)	125	113	145
Liver Stiffness by VCTE ³ (FibroScan) (kPa)	15	14	16
Hepatic Fat Fraction by MRI-PDFF (%)	17.1	18.5	17.5
Alanine Aminotransferase (ALT) (U/L)	62	50	63

Table 2. Study Populations

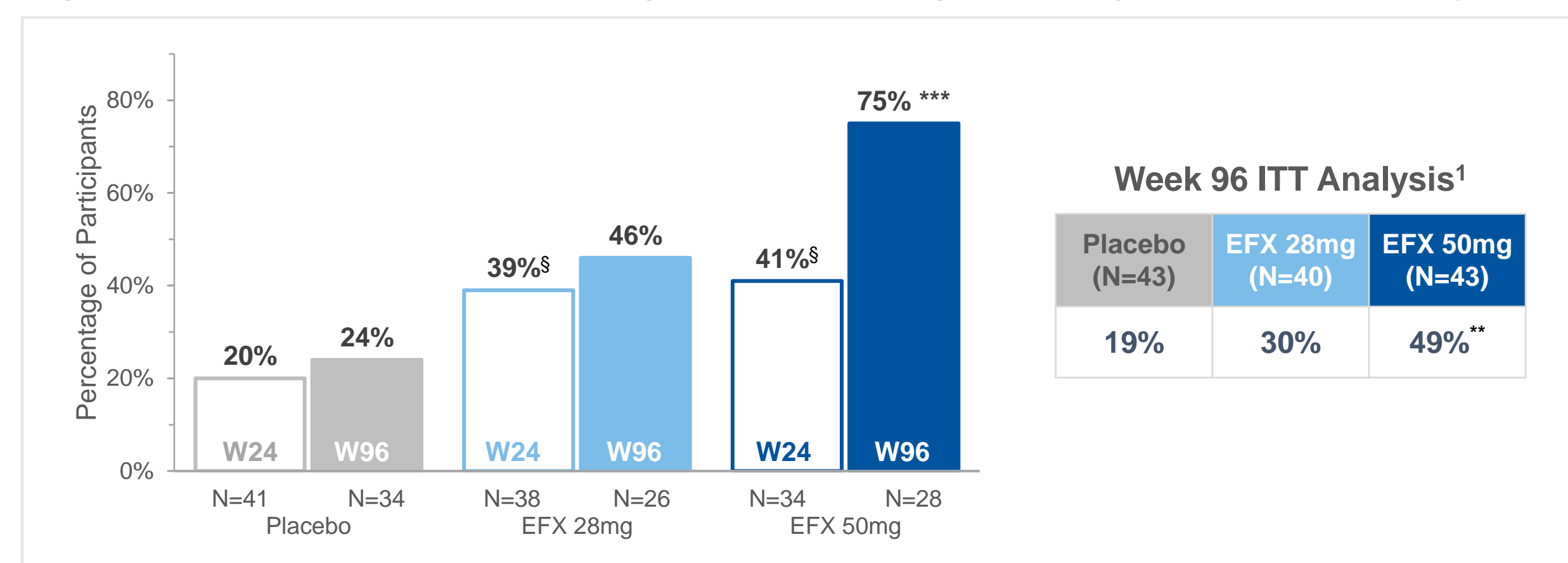
Participants in Specified Analysis Sets (N)	Placebo	EFX 28mg	EFX 50mg
Safety Set / Modified Full Analysis Set (mFAS) ⁴	43	40	43
Week 24 Liver Biopsy Analysis Set (LBAS-24) ⁵	41	38	34
Week 96 Liver Biopsy Analysis Set (LBAS-96) ⁶	34	26	28

¹ All participants either fibrosis stage 2 (F2) or stage 3 (F3); ² Type III collagen N-Terminal Propeptide (GEN 2 ELISA); ³ Vibration-controlled transient elastography; ⁴ All randomized participants who took at least one dose of study drug; ⁵ All Full Analysis Set participants who had baseline and Week 24 liver biopsy results; ⁶ All Full Analysis Set participants who had baseline and Week 96 liver biopsy results.

RESULTS

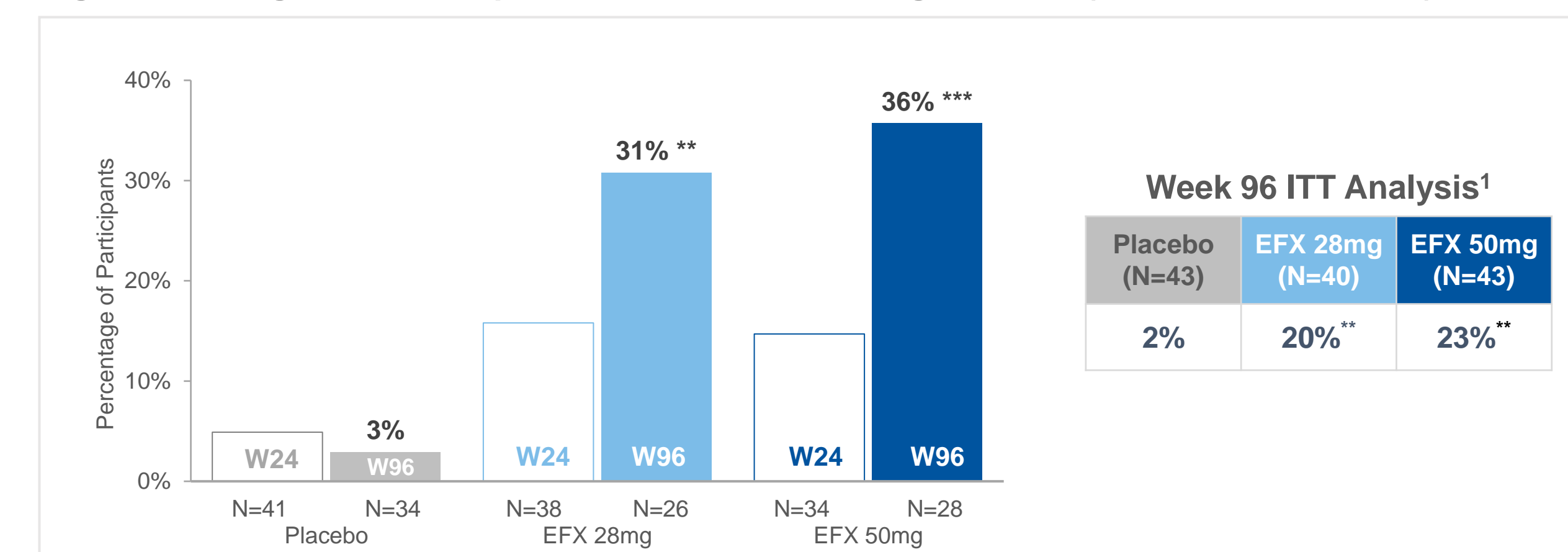
1. Substantial improvement in fibrosis from Weeks 24 and 96 of EFX treatment

Figure 2. Fibrosis Improvement ≥1 Stage & No Worsening of MASH (LBAS-24 or LBAS-96)



[§]p<0.05 versus placebo at week 24, ^{***}p<0.001 versus placebo at week 96 (Cochran-Mantel-Haenszel Test [CMH])
^{**}p<0.01, ^{***}p<0.001 versus placebo at week 96 (CMH)
¹All missing biopsies are imputed as a non-responder.

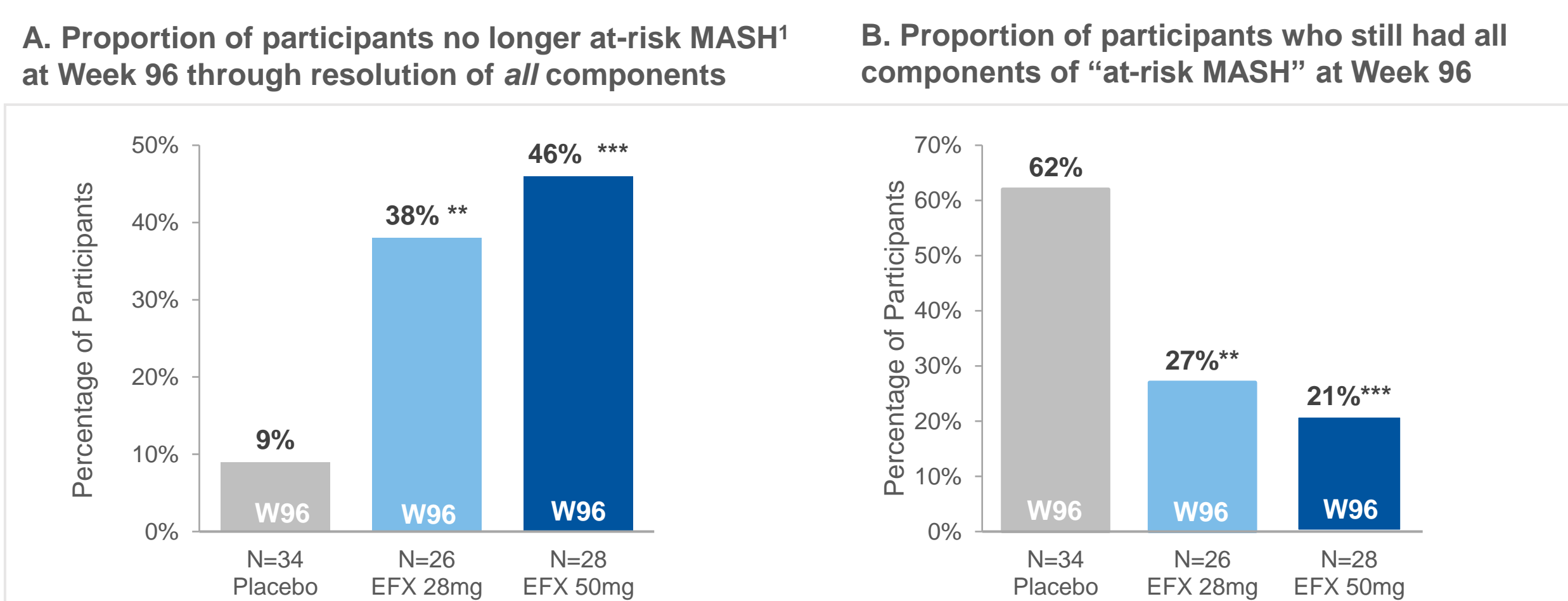
Figure 3. 2-Stage Fibrosis Improvement & No Worsening of MASH (LBAS-24 or LBAS-96)



^{**}p<0.01, ^{***}p<0.001 versus placebo at W96 (CMH).
¹All missing biopsies are imputed as a non-responder.

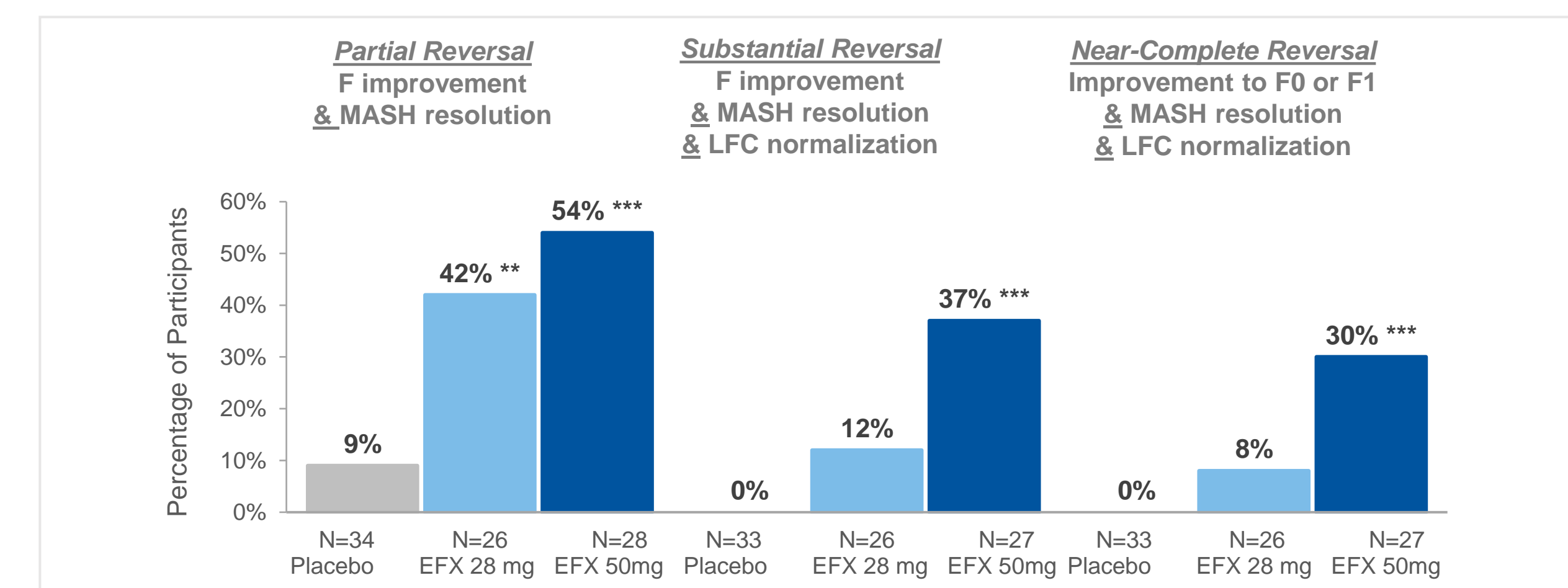
3. Evidence of disease reversal after 96 weeks of EFX 28mg or 50mg

Figure 5. Extent of disease reversal as indicated by presence of "at-risk MASH"



¹ At-risk MASH defined as:
• Definite MASH (≥ 1 point in each of NAS components)
• F≥2 and
• NAS ≥ 4
¹ All participants were at-risk MASH at baseline. Participants that resolved only one or two of the at-risk MASH criteria are not shown. MASH Resolution: defined as a NAS of 0-1 for inflammation, 0 for ballooning, and any value for steatosis. ^{**}p<0.01, ^{***}p<0.001 versus placebo (CMH)

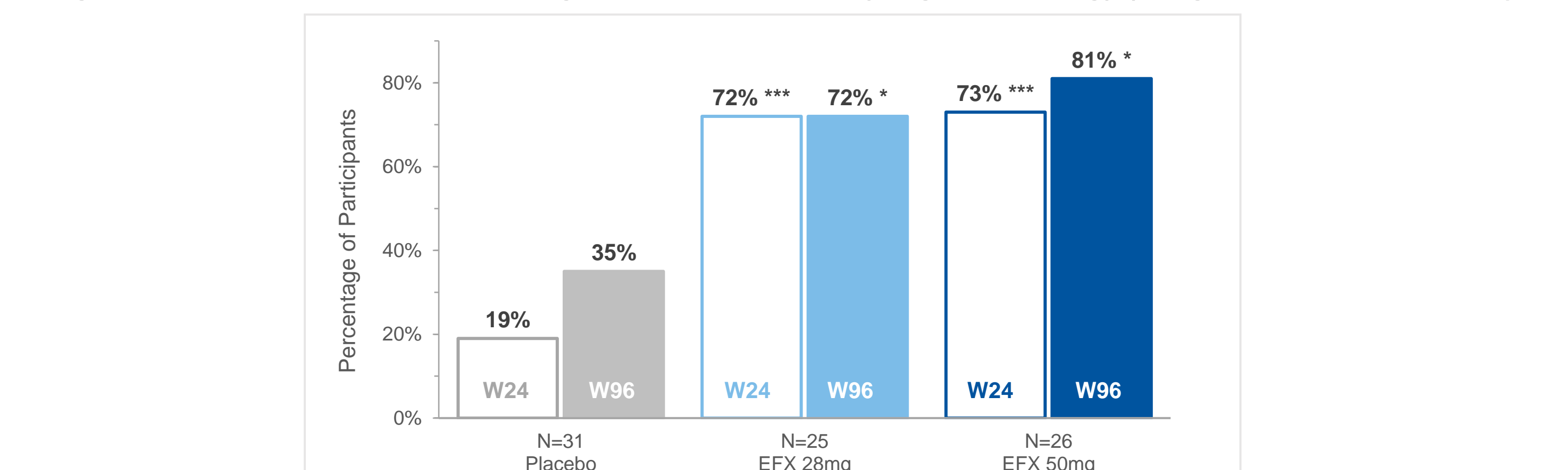
Figure 6. Proportion of participants with partial to complete reversal of disease after 96 weeks



^{**}p<0.01; ^{***}p<0.001 versus placebo (CMH), LBAS-96. MASH resolution defined as a NAS of 0-1 for inflammation, 0 for ballooning, and any value for steatosis. LFC normalization defined as liver fat content ≤5% by MRI-PDFF.

2. Corroboration of conventional histopathology results by digital pathology (qFibrosis®)

Figure 4. Fibrosis Improvement ≥1 Stage at Week 24 and 96 by Digital Pathology (Subgroups of the LBAS-96¹)



[§]p<0.05, ^{***}p<0.001, versus placebo (CMH). ¹Subgroup of the LBAS-W96 with available unstained slides at baseline and W24 suitable for analysis.

4. Evidence of Disease reversal based on established non-invasive clinical tests

Figure 7. Individual-level FAST Scores at Baseline and Week 96 (mFAS)

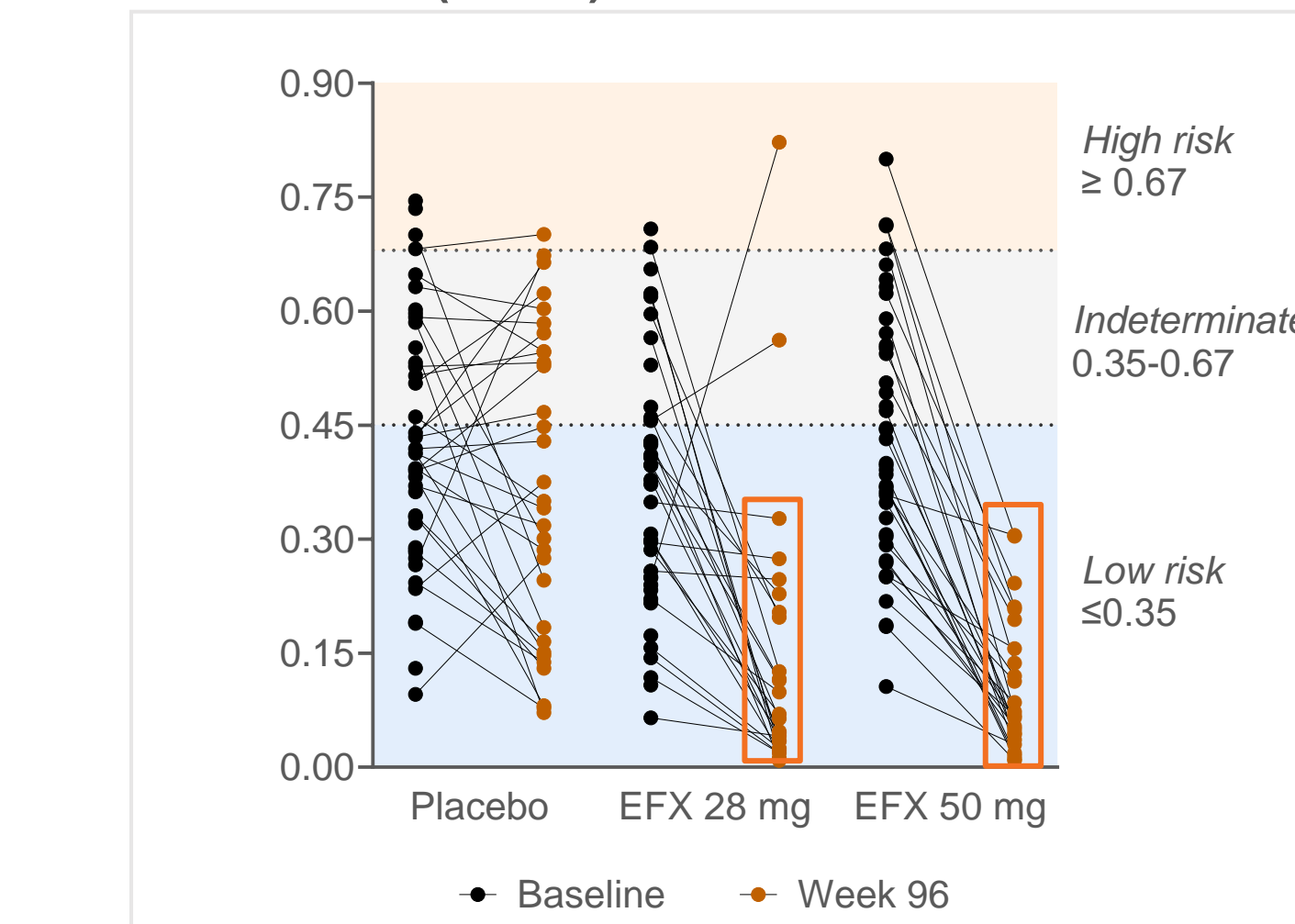
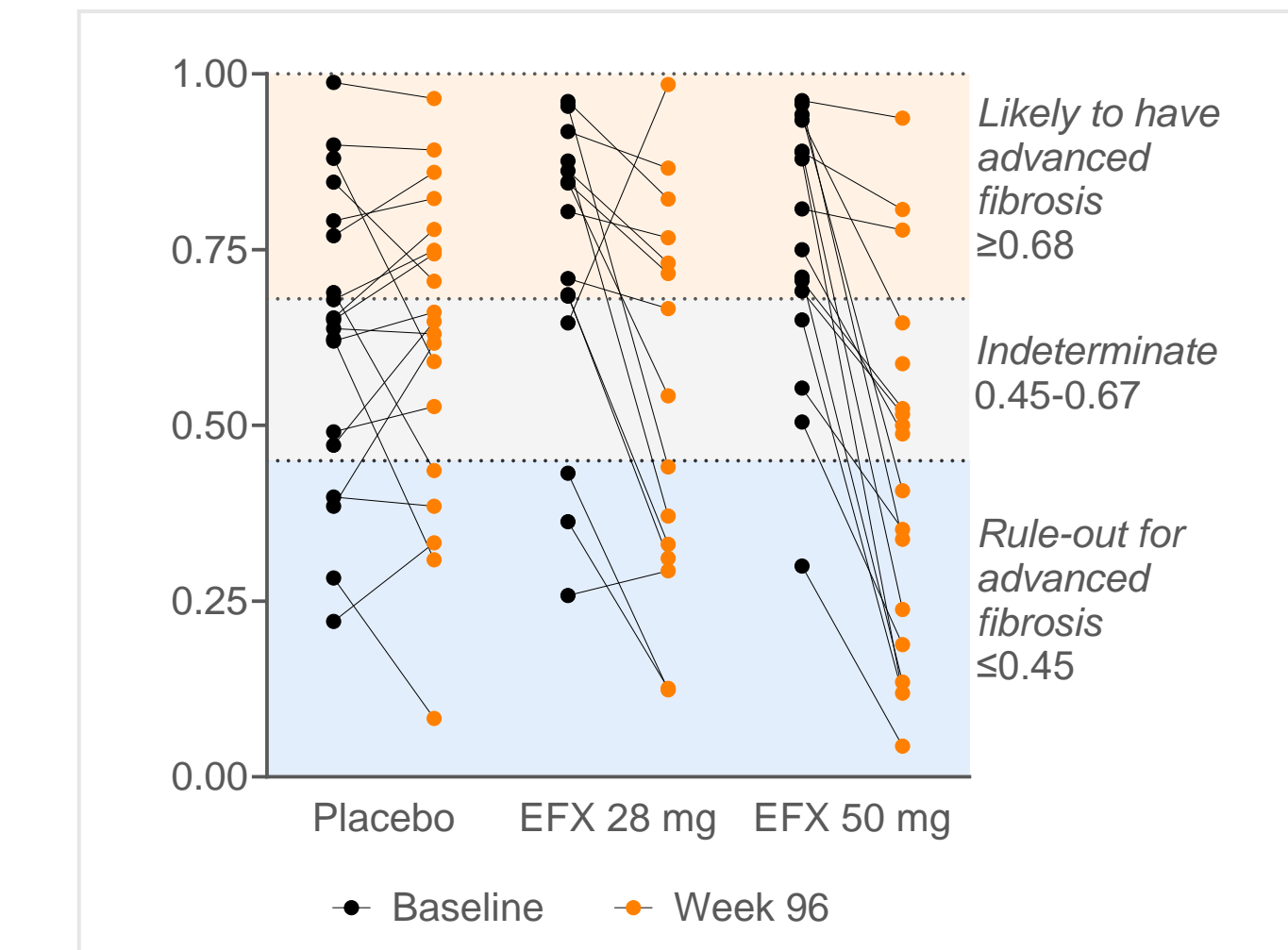


Figure 8. Individual-level AGILE-3+ Scores at Baseline and Week 96 in F3 subgroup (mFAS)



CONCLUSIONS

Unprecedented Antifibrotic Activity Observed for EFX after 96 weeks

- Rapid antifibrotic response to EFX at week 24 was sustained and expanded to a greater proportion of participants after 96 weeks
- 1 in 3 participants treated with EFX experienced a 2-stage fibrosis improvement, over double the proportion at week 24
- AI-based digital pathology (qFibrosis®) corroborated conventional pathologic scores

EFX treatment was associated with disease reversal after 96 weeks

- Significant proportion of subjects were no longer at-risk MASH
- Almost 1 in 3 participants receiving 50mg EFX experienced liver fat normalization, MASH resolution, and improvement to fibrosis stage 0 or 1
- 100% of participants receiving EFX 50 mg were categorized as low-risk of having NAS ≥ 4 and F ≥ 2 based on FAST score
- Improvement in AGILE-3 across most participants with Baseline F3 indicates lower likelihood of advanced fibrosis

AUTHOR DISCLOSURES

CB's institution receives support for biopsy related work and/or consulting agreements with Akero Therapeutics. MN received consulting fees and grant/research support from Akero Therapeutics. DC, EF, BDT, MM, MB, KB, RS, EJT, TR, AC, and KY are employees of Akero Therapeutics. EC, YC, and DT are employees of HI.

ACKNOWLEDGMENTS

Thank you to the participants and their families, Dr. Stephen Harrison, the investigators, and their teams, who participated in the completed HARMONY study.

CONTACT INFORMATION

Kitty Yale, Akero Therapeutics: kyale@akerotrx.com