

## Background and Aims

- Metabolic dysfunction-associated steatohepatitis (MASH) with bridging fibrosis (stage F3) is a critical stage in the evolution of steatotic liver disease, which can progress to cirrhosis or reverse to milder disease with better prognosis.
- Second harmonic generation/two photon excitation fluorescence (SHG/TPEF) microscopy of unstained liver sections with artificial intelligence (AI) provides sensitive and reproducible quantitation of liver fibrosis.
- The aim was to apply SHG digital pathology for quantitative evaluation of liver fibrosis and individual septa parameters in MASH patients with bridging fibrosis (F3 stage) and compare these with conventional histology assessment.

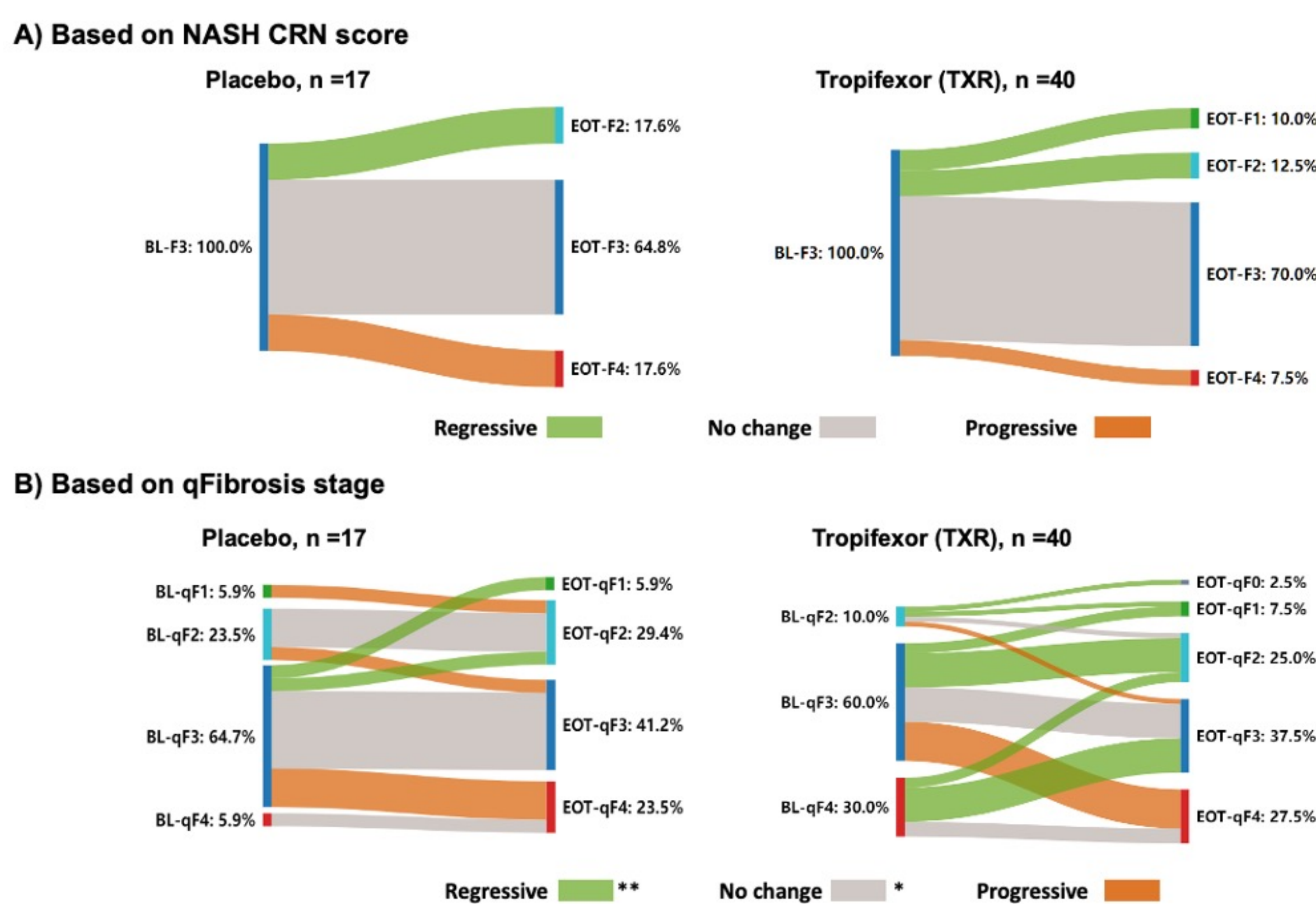
## Methods

- Paired liver biopsies from 57 patients [placebo, n=17 or tropifexor (TXR) n=40], all with bridging fibrosis (F3 stage) according to the CRN scores at baseline (BL) from the FLIGHT-FXR clinical trial (NCT0285164) were included.
- Unstained liver sections from BL and end-of-treatment (EOT) were examined using SHG/TPEF microscopy and liver fibrosis overall, in five different zones of liver lobules, plus 12 septa parameters were quantitatively assessed.

## Results

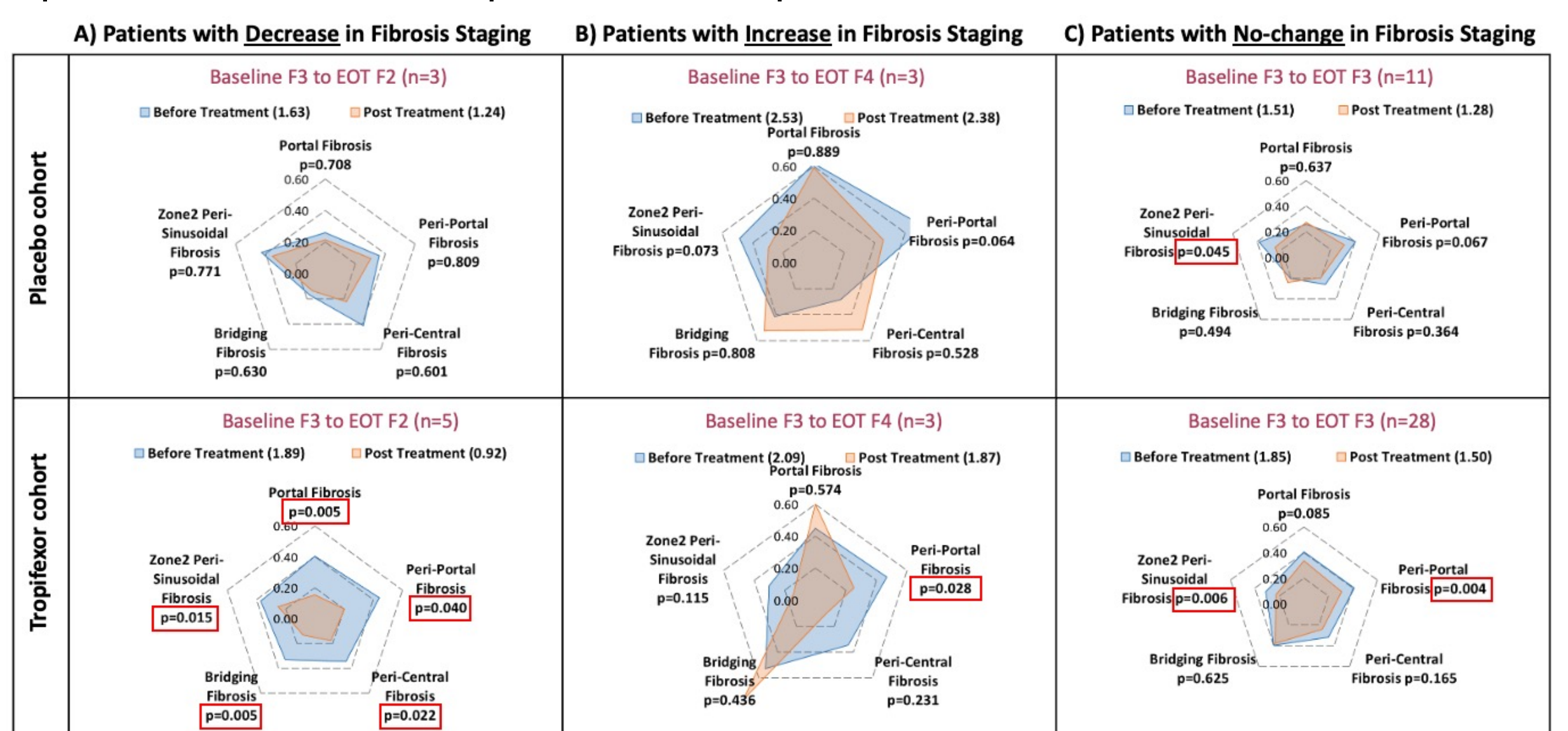
- Figure 1A:** Most cases (65% in placebo, 70% in TXR) were classified as “F3 No-change” according to the NASH CRN.
- Figure 1B:** In contrast, digital quantitation identified greater diversity of fibrosis stage at BL, and a large proportion of cases showed fibrosis progression or regression (Figure 1B) according to qFibrosis stage.

**Figure 1:** Liver fibrosis changes (BL to EOT) as assessed by conventional scoring (NASH CRN) and by qFibrosis using SHG.

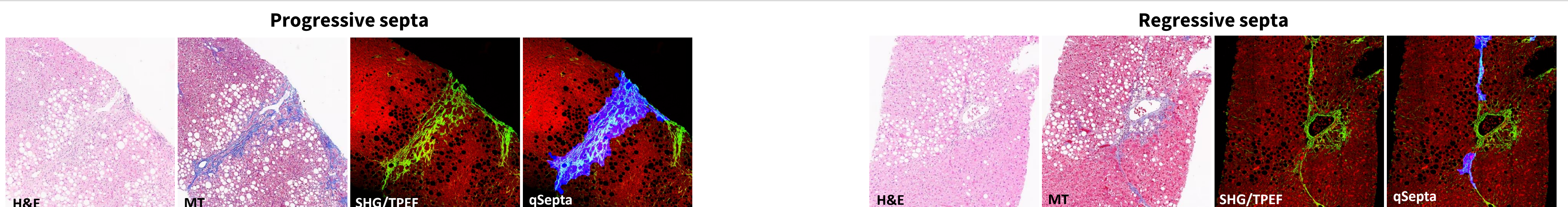


- Additionally, the amount of fibrosis was quantitated in 5 regions of liver lobule – Portal, Peri-portal, Zone 2 Perisinusoidal, Peri-central region, and Bridging fibrosis.
- The results (17 placebo, 36 TXR) were represented by radar maps as an approach for illustrating fibrosis dynamics.

**Figure 2:** qFibrosis changes (BL to EOT) presented as a radar map in patients who received placebo or Tropifexor.



- Patients were divided into 3 subgroups: A) Those whose fibrosis decreased, B) increased, or C) was unchanged from BL to EOT according to NASH CRN scoring.
- The radar map for placebo group revealed significant fibrosis increase in perisinusoidal fibrosis, while in some patients treated with TXR, significant fibrosis reduction was detected in the portal, peri-portal areas and bridging fibrosis.



**Figure 3:** Example of progressive and regressive septa with conventional staining method and digital SHG microscopy of the unstained liver tissue.

## Conclusion

- SHG/TPEF microscopy with AI provides greater granularity and precision in assessing fibrosis dynamics in MASH patients with bridging fibrosis and reveal worsening or improvement undetectable by conventional microscopy, enhancing the understanding of pathogenesis and treatment response.
- These results support the use of digital approaches for quantitative fibrosis assessment, in the natural history and treatment of MASH and other liver diseases.